


**PATIENT**

Lily Visciano

**PRESENTING CLINICAL SIGNS**

 History: Recheck echo. Heart murmur, grade 3/6.  
 -Abnormal lab results: Slight increase in urea, ALT, ALK.  
 -Pertinent previous echo findings (3/2022 MML): mild MR, mild LAE, no LVE, trace TR

**SPECIES**

Canine

**ELECTROCARDIOGRAPHIC FINDINGS** \*Note: Single lead ECGs are evaluated as a rhythm strip. Morphology/MEA cannot be definitively commented on.

A single lead ECG is available; 50mm/s, 20mm/mV. The average heart rate is 120bpm (range 107-136bpm). The rhythm is sinus in origin, with a p for every QRS complex and vice versa. The P and QRS morphologies are positive. No ectopic beats, pauses or other dysrhythmias observed.

**BREED**

Maltese

ECG diagnosis: Normal sinus rhythm

**SEX**

Female Spayed

**ECHOCARDIOGRAM FINDINGS**

2D, m-mode, color flow and doppler imaging is available. Diffuse thickening of mitral valve leaflets with no prolapse into the left atrial lumen. Moderate eccentric mitral regurgitation with mild left atrial dilation. Elevated MR velocity. Normal LV diameter with adequate myocardial function. The tricuspid valve appears normal with trace tricuspid regurgitation. Normal velocity. Normal right atrial and ventricular diameter and morphology indicating no overt evidence of pulmonary arterial hypertension. The pulmonic and aortic valves are normal in morphology and mobility. Normal pulmonic and aortic outflow velocities with laminar flow. No obvious aortic or pulmonic insufficiency. No pericardial or pleural effusion noted. No obvious cardiac masses.

**AGE**

13 years

**WEIGHT**

12.3lbs

**INTERPRETED BY**

 Maggie Machen Lamy,  
 DVM DACVIM  
 (Cardiology)

**CARDIAC CHART**
**IMAGING PERFORMED BY**

Kelly Reschny, RVT

**HOSPITAL NAME**

 Snelgrove Veterinary  
 Service

**REFERRING VET**

Dr. Gunsinger

**INVOICE**

24925

**DATE**

6/22/22

CANINE CARDIAC PARAMETERS	MR VMAX (m/s)	TR VMAX (m/s)	LA/AO (Boon method)	LA/AO (Heart Base; Swe)	FS (%)	EF (%)	EPSS (cm)
NORMAL PARAMETER	4.5-5.5	<2.7	1.3	<1.6	28-40	40-100	<0.6
PATIENT	6.3	2.0	1.1	1.5	38	70	NM
CANINE CARDIAC PARAMETERS	HR (BPM)	AV VMAX (m/s)	PV MAX (m/s)	BODY WEIGHT (kg)	LA 2D short axis Base view (cm)	LVIDd Avg; 2D and m-mode short axis (cm)	LVIDs Avg; 2D and m-mode short axis (cm)
NORMAL PARAMETER	50-100	0.7-1.7	0.7-1.6	BELOW	BELOW	BELOW	BELOW
PATIENT	133	1.6	1.0	5.6	2.0	2.9	1.8
*Normal chamber parameters expressed as a mean value (SD)				3	1.27 (5.3)	2.46 (2.46)	1.36 (5.5)
BODY WEIGHT DEPENDENT PARAMETERS				5	1.40 (4.5)	2.74 (5.2)	1.60 (4.7)
*Note: All measurements based upon multi-modal images and methods. An average value is reported.				10	1.50 (3.8)	3.27 (3.5)	2.06 (3.1)
				15	1.83 (2.0)	3.71 (2.4)	2.43 (2.1)
				20	2.02 (1.9)	4.14 (2.2)	2.80 (2.0)
				25	2.18 (2.4)	4.48 (2.9)	3.10 (2.5)
				30	2.33 (3.3)	4.83 (3.9)	3.39 (3.4)
				35	2.48 (4.3)	5.17 (5.0)	3.69 (4.5)
				40	2.62 (5.2)	5.48 (6.1)	3.96 (5.4)
				50	2.88 (7.1)	6.07 (8.3)	4.46 (7.4)

 Adapted from June Boon, Veterinary Echocardiography, 1998  
 Rishniw M and Hollis NE, J Vet Intern Med 2000; 14:429-435  
 Hansson et al, Vet Rad and Ultrasound 2002  
 Bonagura et al. Echocardiography: principles of interpretation, Vet Clin North Am 15:1177, 1995



**PATIENT**

Lily Visciano

**SPECIES**

Canine

**BREED**

Maltese

**SEX**

Female Spayed

**AGE**

13 years

**WEIGHT**

12.3lbs

**INTERPRETED BY**

Maggie Machen Lamy,  
DVM DACVIM  
(Cardiology)

**IMAGING PERFORMED BY**

Kelly Reschny, RVT

**HOSPITAL NAME**

Snelgrove Veterinary  
Service

**REFERRING VET**

Dr. Gunsinger

**INVOICE**

24925

**DATE**

6/22/22

**INTERPRETATION OF THE FINDINGS & FURTHER RECOMMENDATIONS**

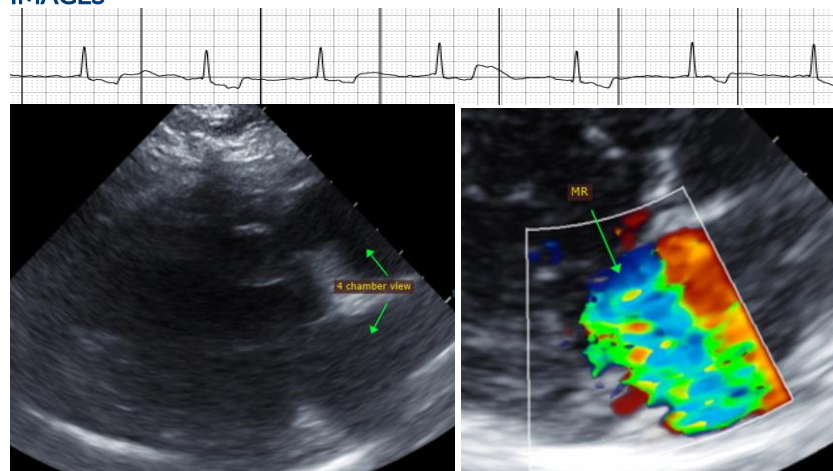
Chronic degenerative valve disease persists with relative stability. While the MR is increased, the left heart dimensions are unchanged. An elevated MR velocity is noted, and a BP is recommended. No additional issues are identified and the ECG is unremarkable with a normal sinus rhythm.

In an asymptomatic dog with no significant left atrial enlargement, no cardiac medications are clearly indicated. Assessment of progression in the future will help predict long term prognosis, which is highly variable at this stage. Omega fatty acid supplementation and mild salt restriction may be of some long-term benefit. Monitor for development of a cough, labored breathing, exercise intolerance or collapse episodes.

Anesthetic risk is considered mild if needed. Cardiac protective drug choices (opioid/benzodiazepine premedication, propofol or alfaxalone induction, isoflurane gas) are recommended. Pre-oxygenate for 5-10 minutes prior to induction. Monitor for arrhythmias, hypotension, and hypoxia both intra and post-operatively and intervene as necessary. Mild IV fluid restriction is recommended to avoid fluid overload. Avoid heart rate stimulating drugs such as atropine unless clinically indicated.

Recommend conservative monitoring with a recheck echocardiogram in 6 months, sooner if any development of clinical signs.

**IMAGES**



The information and recommendations provided are based on the images presented by the referring veterinarian. No evaluation can be communicated regarding pathology that was not visible in the image/video clips provided.

Thank you for this referral. This report was generated using transcription software, and minor dictation errors may be present. If the clinical or image interpretation does not parallel your findings or if I can be of any further assistance, please contact me.

Maggie Machen Lamy, DVM  
Diplomate of the American College of Veterinary Internal Medicine (Cardiology)  
info@sonopath.com